

## An Expansile Large Odontogenic Keratocyst Maxilla: A Case Report.

Nasib Chand Khabra<sup>1</sup>, Ish Pandhi<sup>1\*</sup>, Kiran DN<sup>2</sup>, Sunil Alipuria<sup>1</sup>, Bhawna Gulati<sup>1</sup>, and Aastha Narula<sup>1</sup>.

<sup>1</sup>Department of Pathology, Maharishi Markandeshwar Institute of Medical Sciences and Research, Mullana (Ambala), Haryana, India.

<sup>2</sup> Department of Oral And Maxillo-facial Surgery, Maharishi Markandeshwar Institute of Medical Sciences and Research, Mullana (Ambala), Haryana, India.

### Case Report

Received: 22/01/2014  
Revised: 13/02/2014  
Accepted: 19/02/2014

#### \*For Correspondence

Department of Pathology,  
Maharishi Markandeshwar  
Institute of Medical Sciences  
and Research, Mullana  
(Ambala), Haryana, India.

**Keywords:** Odontogenic  
keratocyst, Maxilla, Keratin

#### ABSTRACT

Odontogenic keratocyst is a common type of tooth derived cyst due to presence of odontogenic epithelium remnant in different regions of jaw. It may be unilocular or multilocular and thus making a total of 31.5% of cystic lesions of jaw. Commonest site is mandible (66.8%) ,however different regions of maxilla can be involved. We report a case of a young patient coming with a swelling in the right cheek area, firm to hard in consistency and progressively increasing in size which was associated with pain and symptoms of nasal blockage. Radiological scans showed odontogenic keratocyst encroaching on maxillary sinus and palate that was later removed surgically and confirmed histologically. Odontogenic keratocyst can be easily confused with other lesions of maxillary sinus as sinusitis or antral polyps, which usually resemble symptomatically. There can be malignant transformation of this benign condition towards squamous cell carcinoma or ameloblastoma. So an early and accurate diagnosis of odontogenic keratocyst is a challenge for pathologists.

#### INTRODUCTION

The odontogenic keratocyst is a common of tooth derived cysts due to presence of odontogenic epithelial remnant in the regions of jaw. It is generally unilocular or multilocular radiolucency, which usually occur in relation to dentigerous lamina. It constitutes nearly 17 % of bone specimens received from maxillofacial Surgery and thus making a total of 31.5 % of cystic lesions of Jaw. The canine region is found to be commonest site followed by anterior maxillary region, 1st & 2nd Molar, 3rd Molar and premolar regions respectively in the frequency of its occurrence [1].

Bi - modal age distribution with additional peak in the fifth and sixth decade of life is seen. However, Cases ranging from 5 - 80 years have been reported. Male preponderance by ratio of 1.6:1/1.3:1 is observed in many studies. It is further divided into peripheral OKC with female to male ratio as 2.2:1 and the intra osseous type with more aggressive clinical course is observed. Sometimes the cysts are found as part of basal cell nevus syndrome called Gorlin-Goltz Syndrome.

Sebaceous differentiation is also seen in certain OKC's ,which contains hard tissue deposits namely dystrophic calcification and cartilage in the connective tissue wall of OKC. Among the differential diagnosis, we have dentinoid forming OKC like odontogenic cyst and dentigerous cysts and tumors such as calcifying OKC and odontoma, ameloblastic fibro-odontoma, central odontogenic fibroma and odontometoid odontogenic tumors [2,3,4,5,6].

#### Case History

History dates back to four months when patient noticed presence of a firm swelling on the right side of the middle third of the face(fig 1a) . On examination, the swelling extended anteroposteriorly from ala of nose to the vertical line 2 cm. posterior to the angle of mouth. Superoinferiorly, it extended from a line 1 cm. above the Ala of tragus line, to a line joining the angle of the mouth to the lobule of the ear. There was an obliteration of the

nasolabial fold. The swelling had smooth margins that blended with its surroundings. The overlying skin temperature was elevated to that of surroundings. None of the Lymphnodes was palpable. The intra oral examination showed an intra oral swelling present in the maxilla on the right side. Vestibular obliteration was present with swelling in a relation to right 543 region. The surface of the swelling was positive for blanking and extended from buccal to palate region. The swelling was compressible intraorally and there was seen expansion of both cortical plates. On percussion, none of the regional teeth was tender. A provisional diagnosis of globulomaxillary cyst, Radicular cyst or infected cyst was made. Later the cyst was removed by marsupialisation followed by cautery. The patient is on follow up since surgical intervention.

## DISCUSSION

The OKC's have distinct microscopic appearances, which differentiates it from other cystic lesions occurring in the some other regions. Characteristically, it has a uniform odontogenic epithelial layer, which lacks rete-ridges and has corrugated parakeratinised luminal layer, that is a prominent layer of basal cells (Figure 1) The luminal space is usually filled with keratin material, which may show presence of chronic inflammatory infiltrates. The cavity of OKC may be uniloculated or multiloculated.

The OKC's are of utmost clinical importance because of its high rate of recurrence after surgery, which may range from 13 % to 60 % and its future development as highly aggressive behaviour than any other types of Jaw cysts 4 -8 -10. Mostly the affected patients are usually in the 2<sup>nd</sup> & 3<sup>rd</sup> decade of life. 11-13

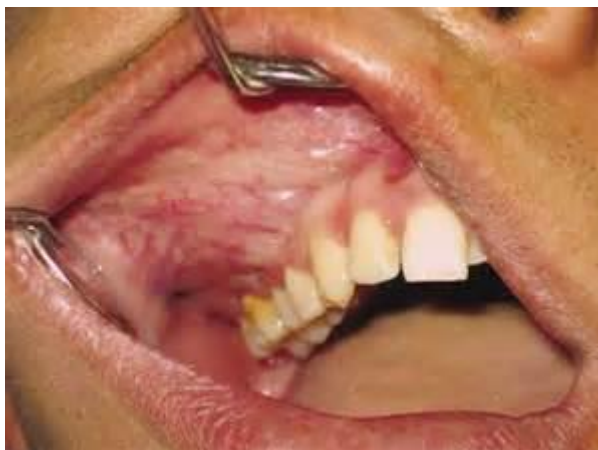Radiologically OKC's usually appear as well defined radiolucencies which can be either unilocular & multilocular cyst 14. The unilocular cyst is located periapically and thus simulating periapical cysts 14 -15 -16. Surrounding the crown of unerupted tooth (Figure 3) and thus mimicking dentigerous cyst 11-17, between the roots of teeth (lateral periodontal or lateral Radicular cyst 18. In the maxillary midline simulating nasopalatine duct cyst 9. Single large unilocular OKC can be confused with cystic ameloblastoma 20 -21. Routine radiography is sometime inadequate in most cases to determine the site & size of OKC. However advanced imaging techniques like CT & MRI can be beneficial in large and complicated OKC's involving maxillary sinus and more rarely, when it involves the base of skull. 22-24

Many studies conducted in lieu of clinical presentation of OKC, the mandible is involved more often than maxilla 4 -8-11-13-28-31. Additionally, posterior part of mandible is most common location for OKC 8-11-12 -25-27. In one study, the OKC's are divided equally between anterior & posterior maxilla 25-28. Others conclude the posterior maxilla is the predominant site. 13-29-32. Among the studies conducted the mandibular region in the lower jaw was found to be most common site for OKC's (66.8%) The remaining percentages of OKC's were found in the maxillary region making the ratio of 2:1, which coincides with the previous studies. According to the latest WHO classification, the OKC is categorized as a developmental inflammatory odontogenic cyst 6. that arise from rest of the dental lamina 7.

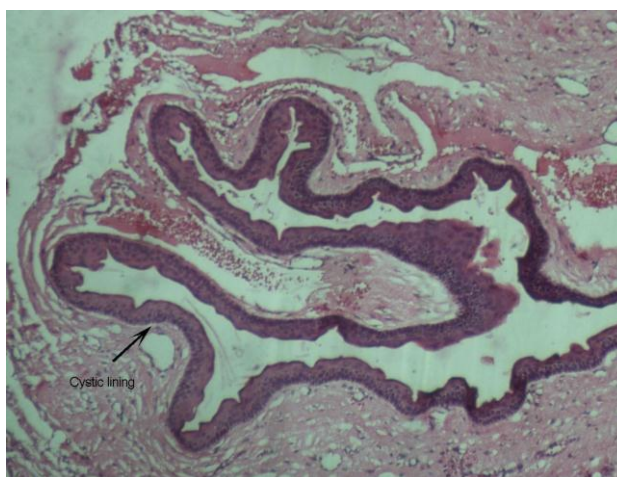
In the present case, we are presenting a rare case of OKC arising from the right anterior maxillary alveolus in the area of lateral incisors and canine. Radiologically, the simple radiograph of 543 regions shows displacement of regional teeth and bilamellar expansion of region along with right lateral space involving the apices of premolars causing displacement of regional teeth.

Computerized tomography (axial and coronal views) shows large expansile lytic lesion arising from right maxillary alveolus in the area of lateral incisors and canine. The cystic contents of the lesion show no fluid. The lesion is expanding erosively and causing thinning of the lingual and buccal cortex (Fig. 4). The lesion is extending superiorly to the right maxillary sinus and also involves the hard palate superomedially. (Fig. 5) There is an evidence of bony erosion in the antero-inferior portion in the cheek area. The definite diagnosis can be made only by histopathological examination although clinical and radiographic features may allow fairly accurate preoperative diagnosis.

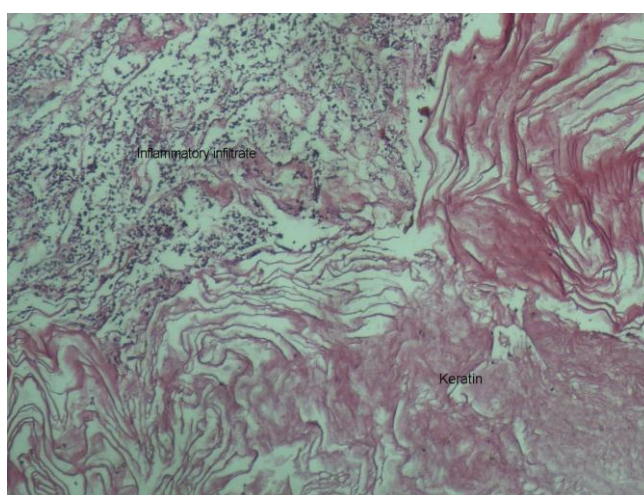
The microscopic study of osseous tissue revealed lining outer basal epithelial layer of odontogenic origin, which is devoid of rete ridges (Fig. 1). The luminal space is filled with flakes of keratin material (Fig. 2) with an area of extensive chronic inflammatory infiltrate comprising mainly of lymphocytes and plasma cells. An unerupted tooth is also seen (Fig. 3) [7,8,9,10].



**Figure 1:** H&E stained section shows low power of a typical OKC with thin uniform keratinized stratified squamous epithelium in the separating thin connective tissue and osseous background



**Figure 2:** H& E stained picture of higher magnification showing extensive keratin and an area of chronic inflammatory infiltrate



**Figure 3:** H&E stained section shows an unerupted tooth

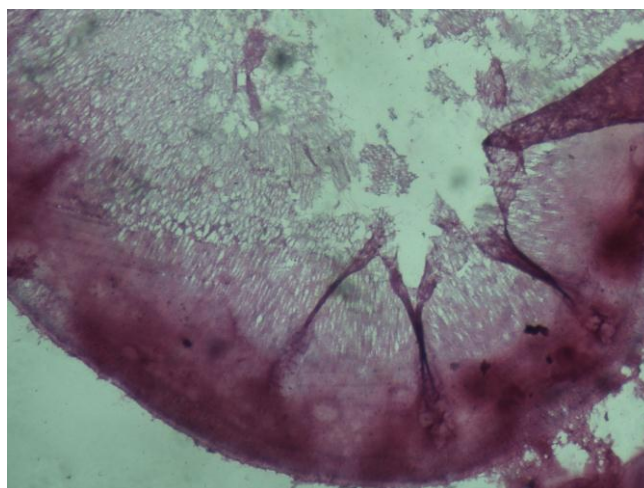


Figure 4: CT scan shows a large lytic expansile lesion in the area of right lateral incisors and canine with no fluid in the cystic contents

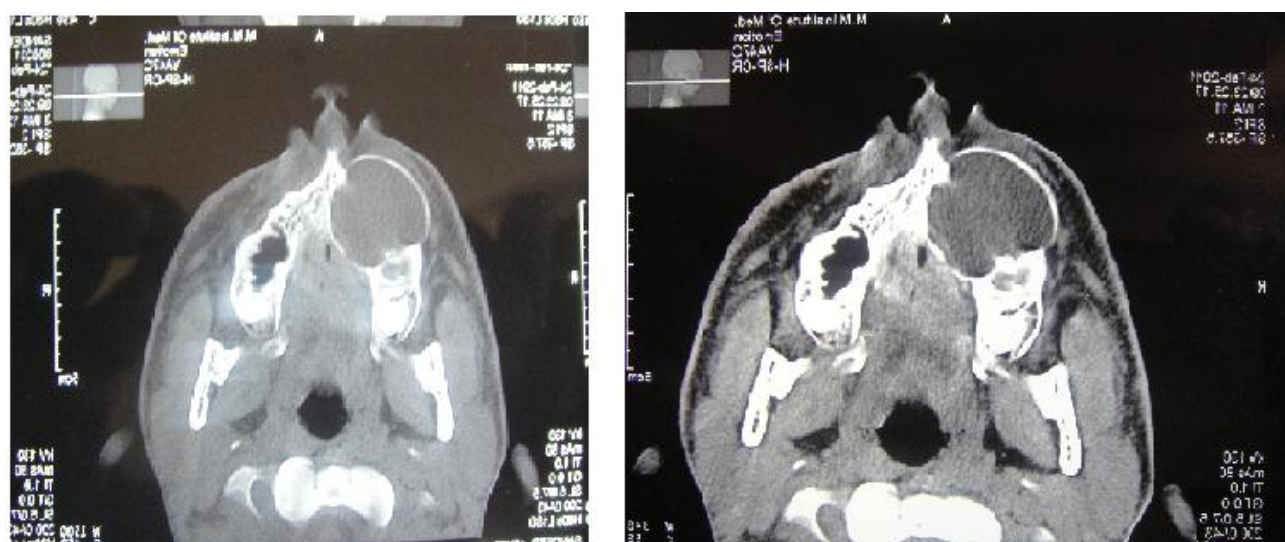

Figure 5: CT scan showing radiolucent area extending to right nasal cavity, maxillary antrum and right orbit

### CONCLUSION

The maxillary OKC is a benign lesion, which commonly involves the canine region, where it can be easily misinterpreted with apical inflammatory lesions or periodontal cysts and more commonly with maxillary sinus lesions such as sinusitis and antral polyps, which symptomatically may resemble. So the accurate histological diagnosis is necessary for proper treatment and most importantly, follows up for future recurrences and malignant transformation to squamous cell carcinoma.

### REFERENCES

1. Ali M, Ronald A. maxillary odontogenic keratocyst: A common and serious clinical misdiagnosis. J Am Dent Assoc. 2003;134:877-83.
2. Darley TD, Wysocki GP, Pringle GA. Relative incidence of odontogenic tumors and oral and jaw cysts in a Canadian population. Oral Surg Oral Med Oral Pathol. 1994;77:276-80.
3. Haring JI, Van Dis ML. odontogenic keratocyst: a clinical, radiographic and histopathologic study. Oral Surg Oral Med Oral Pathol. 1988;66:145-53.
4. Anand VK, Arrowood JP, Krolls SO. Odontogenic keratocyst: a study of 50 patients. Laryngoscope. 1995;105:14-16.
5. Chen C-H, Lin CC. Clinical and histopathological study of the odontogenic keratocyst - a follow up study of 16 cases. Kaohsiung J Med Sci. 1986;2:601-7.
6. Brannon RB. The odontogenic keratocyst: a clinicopathologic study of 312 cases, part I - clinical features. Oral Surg Oral Med Oral Pathol. 1976;42:54-72.

7. Kerim O, Tolga S, Metin S. A large odontogenic keratocyst containing a third molar tooth in the maxillary antrum. Turk J Med Sci. 2005;35:341-46.
8. El-Hajj G, Anneroth G. Odontogenic keratocysts – a retrospective clinical and histological study. Int J Oral Maxillofac Surg. 1996;25:124-29.
9. Marzella ML, Poon CY, Peck R. Odontogenic keratocyst of the maxilla presenting as periodontal abcess. Singapore Dent J. 2000;23:45-8.
10. Dolphine OD, Valiente R, Ghanee N, Kenny EA, Dawson KH. Odontogenic keratocyst: The northwestern USA experience. J Contemp Dent Pract. 2000;1(2):1-10.