

Heterotrophic Pregnancy– Rare Presentation

AB Chattopadhyay¹, Somshekhar Sharma^{2*}, and Kushagra Garg²¹Faculty of Medicine, AIMST University, Malaysia.²Riddhi Multi speciality General Hospital, Mumbai, Maharashtra, India.

Article

Received: 15/02/2013

Revised: 13/03/2013

Accepted: 12/04/2013

***For Correspondence**Riddhi Multi speciality General
Hospital, Mumbai, Maharashtra,
India.**Keywords:** heterotrophic,
pregnancy**ABSTRACT**

Heterotopic pregnancy, a potentially dangerous and life-threatening clinical associated with intrauterine (IU) and extra uterine pregnancies at the same time. Incidence of such cases are rare but very often missed as the diagnosis being overlooked during examination of the pregnant women with risk factors for an ectopic pregnancy such as free fluid with or without an adnexal mass or acute abdominal pain and shock presentation. Hence a high degree of clinical evaluation is warranted examining the pregnant women. In Present paper we report a case with rare presentation as heterotopic pregnancy from emergency hospital of teaching hospital.

CASE REPORT

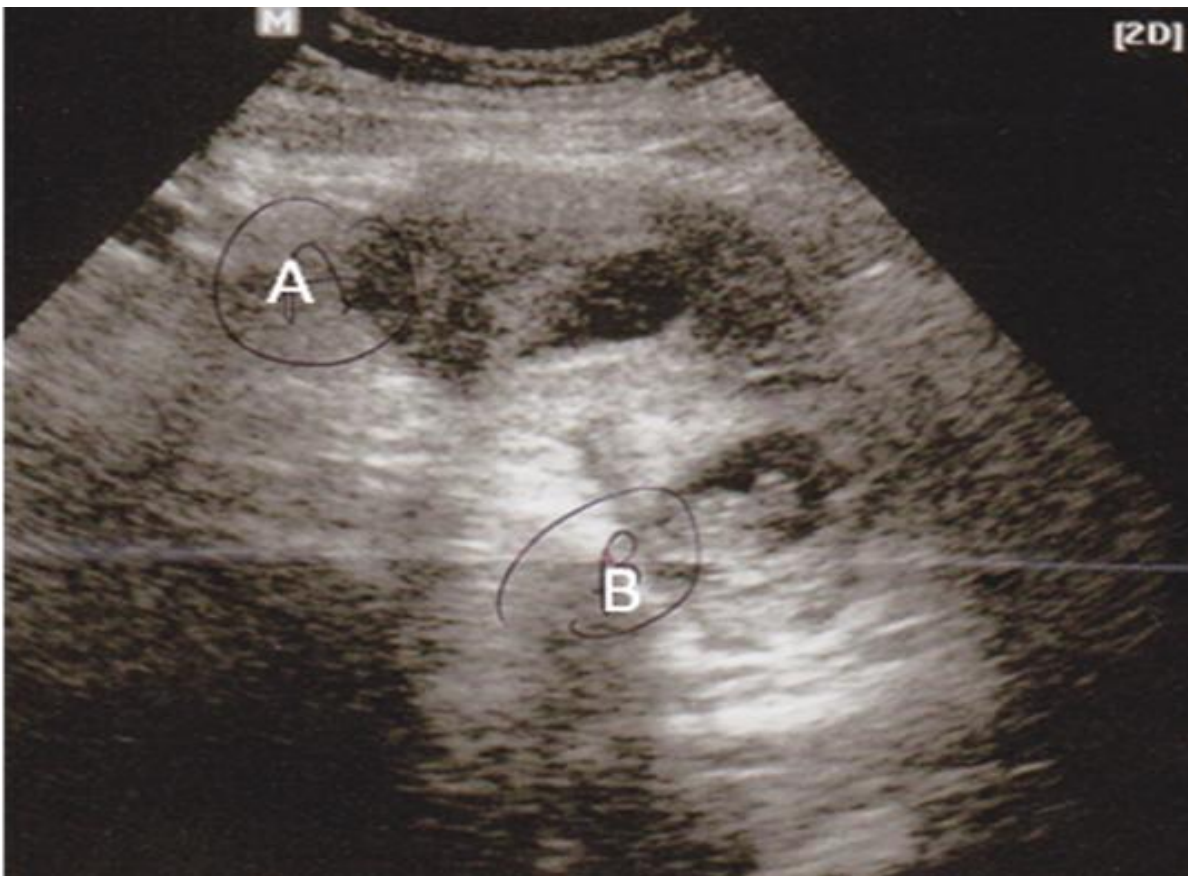
A 29-year-old woman, gravid II Para I, was brought to the hospital with complaints of discomfort of lower abdomen and spotting for the last 2 weeks. The patient was admitted on 12th June 2012 for investigation and management. The medical history of the patient reveals spontaneous conception having 5 wks amenorrhea. Patient had vaginal bleeding for the last 1 day prior to spotting for 2 wks. No treatment was taken by the patients during the period of spotting. On physical examination, the patient was found to be normotensive having blood pressure 120/70 mm Hg, pulse rate-110. There abdominal examination of the patients showed tenderness on lower abdomen. The patient was admitted for further investigation as case of? Twin pregnancy/threatened abortion. The laboratory investigations of the patient reveal Hb-9.1 gm%, blood urea-2.5, Serum creatinine-133, serum K+-4.6, PT-13.6. The patient was stabilized with administration of IV Fluids and sedatives. After hemodynamic stabilization of the patients, an abdominal ultrasonography (US) was performed. The USG finding reveals two gestations one being present in Fallopian tube while the other one was found in uterus. The fetal heart activity could be heard in uterine pregnancy (B) but completely lacking in fallopian tube (A). Gestational age of both the pregnancy was estimated to be 5-7 weeks.

DISCUSSION

Heterotopic pregnancy is defined as the presence of simultaneous live intrauterine and abdominal pregnancies, with one being present in the uterine cavity and the other outside the uterus, commonly in the Fallopian tube and uncommonly in the cervix or ovary [1]. Though its incidence is 1 in 30,000 pregnancy, its occurrence is seen about 6 % of all pregnancies [2]. The first heterotrophic pregnancy was reported as incidental autopsy finding in 1708[3]. Recently it is found that incidence of heterotrophic pregnancy is increasing as 1 in 300 pregnancy with use of assisted reproductive technologies (ART) in infertile couples, such as in vitro fertilization (IVF) and gamet intra fallopian transfer (GIFT) [3].

The present case was diagnosed at 5 weeks without presence of usual presentation of sign and symptoms. There are number of reports of initial failure in diagnosis of heterotopic pregnancies with wide variations in clinical presentations, leading to confusion and misinterpretation of finding [4, 5, 6]. Tal *et al.* [7] reported that accuracy of diagnosing of the heterotopic pregnancies between 5 and 8 weeks of gestation is about 70% and it becomes difficult as gestational age increases. Though it is reported that heterotopic pregnancy is usually has four common presenting signs and symptoms such as abdominal pain, adnexal mass, peritoneal irritation and an enlarged uterus [8] but its presentation has been found quite different in different studies [3,5,9,10,11]. Abdominal pain was reported in 83% and hypovolemic shock with abdominal tenderness was reported in 13% of heterotopic pregnancies. In addition, half of the patients did not complain of vaginal bleeding in another report. Retrograde vaginal bleeding has also been reported may be due to the intact endometrium in some of the IU pregnancies [9]. The present case of heterotrophic pregnancy was found to be associated with sustained complaints of spotting over two weeks without any peritoneal irritation, adnexal mass or enlargement of uterus. There were neither signs of hemodynamic imbalance nor any other complications such as hypotension, dyspnea, thus making difficult to think as a case of heterotrophic pregnancy. It was transvaginal sonography (TVS) which has been proved to be a valuable tool in this case to enable us to help in diagnosis of this case inspite of limited sensitivity of TVS in diagnosis of this condition. The patients was however taken up for surgery and left sided salphingiography was done for evacuation IV pregnancy . post operatively patients was dishcharged without any complications.

We therefore of the opinion that the present cases was of rarest in nature considering its unusual presentation and suggests that TVS is very important tool which should be used to diagnosed such case.



REFERENCES

1. Govindarajan MJ, Rajan R. Heterotopic pregnancy in natural conception. *J Hum Reprod Sci.* 2008;1:37-8
2. Ikeda SI, Sumiyoshi M, Nakae M, Tanaka S, Ijyuin H. Heterotopic pregnancy after in vitro fertilization and embryo transfer. *Acta Obstet Gynecol Scand.* 1998;77:463-4.
3. Bright DA, Gaupp FB. Heterotopic pregnancy: a reevaluation. *J Am Board Fam Pract.* 1990;3:125-8
4. Varras M, Akrivis c, Hadjopoulos G, Antoniou N. Heterotopic pregnancy in a natural conception cycle presenting with tubal rupture: a case report and review of the literature. *Eur J Obstet Gynecol Reprod Biol.* 2003;106:79-82

5. S Chowdhury1, T Chowdhury. Heterotopic Pregnancy: A Clinical Case Report; Bangladesh Med J. 2010;39(3).
6. Wong CM, Ganesh R, Nq KY. Ectopic pregnancy: uncommon presentations with difficulty in diagnosis. Med J Malaysia. 1999; 54 (1): 117-119.
7. Tal J, Haddad S, Gordon N, Timor-Tritsch I. Heterotopic pregnancy after ovulation induction and assisted reproductive technologies: a literature review from 1971 to 1993. Fertil Steril. 1996;66:1-12.
8. Cohen J, Mayaux MJ, Guihard-Moscato MI, Schwartz D. In vitro fertilization and embryo transfer, a collaborative study of 1163 pregnancies to the incidence and risk factors of ectopics pregnancies. Hum Reprod. 1986;4:255-8
9. Dundar O, tutuncu L, Mungen E, Muhcu M, Yergok YZ. Heterotopic pregnancy: Tubal ectopic pregnancy and mono chorionic monoamniotic twin pregnancy: A case report. Perinat J. 2006;14:96-100
10. Adekanle DA, Ekomaye H, Olitan PB. Heterotopic Pregnancy with a live female infant: a case report. The Internet Journal of Gynecology and Obstetrics. (Homepage on internet) 2007; 7(1)
11. El-Nafaty AU, Melah GS, Massa AA, Yahaya UR, Bukar M, Kizaya DD. Heterotopic pregnancy in a natural connection cycle. A case report. Nigerian J Clin Pract. 2005; 8(2): 128-129.