

RESEARCH AND REVIEWS: JOURNAL OF DENTAL SCIENCES

Distribution of Various Developmental Dental Anomalies in Uttar Pradesh: A Hospital Based Study.

Shalini Gupta^{1*}, Kavita Nitish Garg², Amay Tripathi³, and Om Prakash Gupta⁴

¹Department of Oral Pathology and Microbiology, King George's Medical University, UP, Lucknow, India.

²Department of Oral Pathology, Chandra Institute of Dental Sciences, Barabanki, India.

³Rama Dental Clinic, UP, Lucknow, India.

⁴Department of General Surgery, Carrier Institute of Medical Sciences, Lucknow, India.

Research Article

Received: 02/06/2014

Revised : 14/06/2014

Accepted: 20/06/2014

*For Correspondence

Department of Oral Pathology and Microbiology, King George's Medical University, UP, Lucknow, India.

Keywords: Developmental dental anomalies; microdontia; supernumerary teeth; accessory cusp; Anomalies.

ABSTRACT

To investigate Developmental anomalies of teeth are clinically evident abnormalities. They may be the cause of various dental problems. Careful observation and appropriate investigations are required to diagnose the condition for appropriate treatment. Developmental dental anomalies are an important category of dental morphologic variations. All patients attending the outpatient department were screened for the presence of anomalies. A comprehensive clinical examination was carried out to identify the presence of microdontia, macrodontia, talon cusp, fusion, dens invaginatus, accessory cusp, transposition and supernumerary teeth. In the present study, A total of 130 patients were included in the group and the casts were prepared with informed content. Out of which total of 93 casts were of maxillary and 37 of mandibular. This group consists of 78 male and 52 female patients. Developmental dental anomalies are marked deviations from the normal color, contour, size, number, and degree of development of teeth. Local as well as systemic factors may be responsible for these developmental disturbances. Such influences may begin before or after birth, hence deciduous or permanent teeth may be affected.

INTRODUCTION

Developmental anomalies of teeth are clinically evident abnormalities. They may be the cause of various dental problems. Careful observation and appropriate investigations are required to diagnose the condition for appropriate treatment ^[1]. Developmental dental anomalies are an important category of dental morphologic variations ^[2]. They are marked by deviations from the normal color, contour, size, number and degree of development of teeth. Local as well as systemic factors are responsible for these developmental disturbances. Such influences may begin before or after birth, hence deciduous or permanent teeth may be affected ^[1]. Abnormalities in tooth size, shape, and structure result from disturbances during the morpho-differentiation stage of development, while ectopic eruption, rotation and impaction of teeth result from developmental disturbances in the eruption pattern of the permanent dentition ^[3].

Various studies reported the distribution of various dental anomalies in different populations, but the results are conflicting. The discrepancies in their results were attributed to racial differences, variable sampling techniques, and different diagnostic criteria ^[4,5,6,7].

The purpose of this study was to determine the distribution of selected developmental dental abnormalities in shape, structure, number and position of teeth in a population based on statistical analysis; these data are expected to contribute to the dental literature.

SUBJECTS AND METHODS

The study was based on clinical examination and evaluation of dental casts of Uttar Pradesh, Indian subjects, who visited the outpatient department at KGMU, Lucknow between June, 2011- May, 2012, after obtaining their informed consent. All patients attending the outpatient department were screened for the presence of anomalies. A comprehensive clinical examination was carried out to identify the presence of microdontia, macrodontia, talon cusp, fusion, dens invaginatus, accessory cusp, transposition and supernumerary teeth.

Exclusion criteria were selected and only subjects of Indian origin were selected. A comprehensive clinical examination was carried out to identify the presence of selected anomalies. Dental impressions were taken using alginate. Casts were immediately processed with dental stone.

Exclusion criteria

The following groups were excluded from the study:

- Patients belonging to the pediatric age group (under the age of 14 years).
- Patients with history of extraction or orthodontic treatment
- Patients with syndromes such as Down's syndrome, ectodermal dysplasia, etc.
- Patients having cleft lip and palate.
- Dental anomalies secondary to structure, i.e. hypoplasia secondary to amelogenesis imperfecta, dentinogenesis imperfecta, or dental fluorosis.

RESULTS

A total of 130 patients were included in the group and the casts were prepared with informed content. Out of which total of 93 casts were of maxillary and 37 of mandibular. This group consists of 78 male and 52 female patients.

The distribution of various anomalies among male and female patients is outlined in Table 1.

Table 1: Sex Distribution

	Male	female	total
Maxillary	59	37	96
Mandibular	19	15	34
Total	78	52	130

Figure 1: Sex Distribution Microdontia maxillary

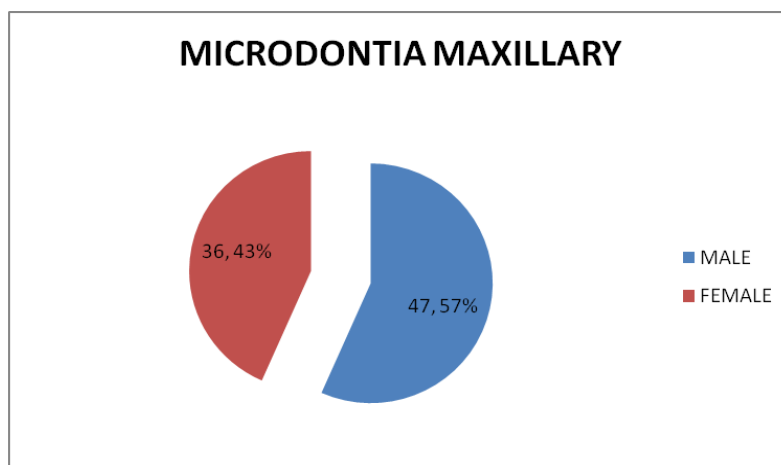


Figure 2: Male and Female ratio in microdontia mandibular and maxillary

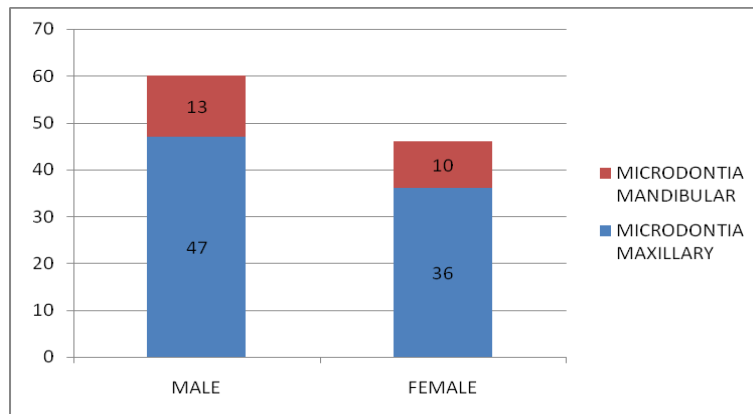


Table 2: list of various anomalies in maxillary dentition

Anomaly	Male	female	Total
Microdontia	30	23	53
Talon cusp	7	5	12
Extra cusp	4	2	6
Transposition	5	1	6
Fusion	4	2	6
Malposition	3	2	5
Macrodonatia	3	2	5
Supernumerary	3	0	3
Total	59	37	96

Table 3: List of various anomalies in mandibular dentition

Anomaly	Male	Female	Total
Microdontia	8	7	15
Extra cusp	1	0	1
Transposition	1	0	1
Fusion	7	6	13
Malposition	2	2	4
Total	19	15	34

Figure 3: Frequency of various anomalies

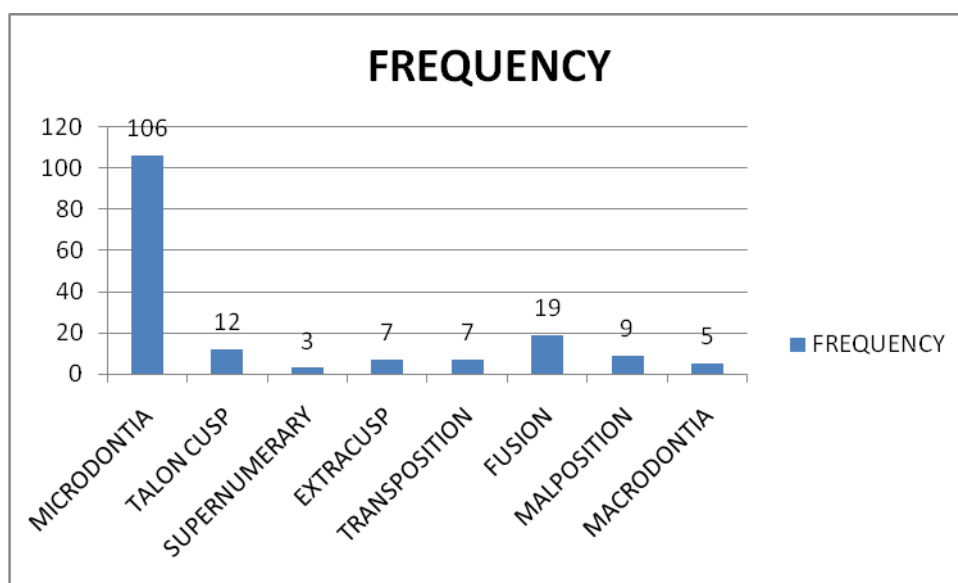


Table 4: Frequency of various anomalies

Anomalies	maxillary	mandibular	total	
Microdontia	53	15	68	
Talon Cusp	12	0	12	
Extra Cusp	6	1	7	
Transposition	6	1	7	130
Fusion	6	13	19	
Malposition	5	4	9	
Macrodontia	5	0	5	
Supernumerary	3	0	3	
Total	96	34	130	

DISCUSSION

Developmental dental anomalies are marked deviations from the normal color, contour, size, number, and degree of development of teeth. Local as well as systemic factors may be responsible for these developmental disturbances. Such influences may begin before or after birth, hence deciduous or permanent teeth may be affected [1]. Dental anomalies of developmental origin reflect a change either in the number, size, shape, or location of teeth, or structural changes. Dental anomalies could appear as isolated, or related to various other syndromes. Dental anomalies can be congenital or acquired. The causes of these anomalies are shown in table 5 [8].

Table 5: Causes of developmental dental anomalies

Congenital anomalies	Acquired anomalies
Heritage (approximately one quarter)	Malnutrition (energetic and protein deficit)
Multi causal etiology (rest)	Influence of chemical substances medicines, vitamins, etc. (3-4%)
External factors (only 1%)	Infections, especially of viral etiology (2-3%)
	Disturbances of metabolism (2%)

Our study includes 130 cases of dental anomalies (Table 1, figure 1). The most common dental anomalies found in the group were as follows: 52.3% microdontia, 14.6% fusion, 9.2% talon cusp, 6.9% malposition, 5.4% extra cusp, 5.4 % transposition, 3.8% macrodontia and 2.3 % supernumerary which included both maxillary as well as mandibular dentition.

Microdontia

It is considered to exist if one, or more teeth are smaller than those considered to be within normal range; that is, they are outside the usual limits of variation [9]. Teeth commonly affected are maxillary lateral incisors and third molars. The prevalence of this condition ranges from 0.8% to 8.4% in various populations [10]. In present study we found 53 cases of microdontia in maxillary dentition and 15 in mandibular dentition. Over all 52.3 % of microdontia was found in our study. When lateral incisors are affected, there is a reduction in mesiodistal diameter and convergence towards the incisal edge and this is referred to as peg shaped incisors. The condition is largely of genetic origin. In the present study, microdontia constituted of total anomalies with a majority of peg shaped lateral incisors & third molar.

Talon Cusp

Talon cusps are morphologically well delineated and extend at least half the distance from the cemento-enamel junction to the incisal edge of the primary teeth. This dental anomaly was firstly described as a process of horn-like shape curving from the base to the cutting edge on the palatal surfaces of the incisors [11]. In the present study, talon cusp constituted 9.2% of all of the anomalies, in which purely 12 cases were seen in maxillary teeth. Its prevalence ranges from less than 1% to 8% of the population [12] with a higher frequency in males than females Hattab et al classified [13] anomalous cusps into three types based on the degree of cusp formation and extension:

Talon

A morphologically well-delineated additional cusp that prominently projects from the palatal surface of a primary or permanent anterior tooth and extends at least half the distance from the CEJ to the incisal edge.

Semi talon

An additional cusp of 1 mm or more, but extending less than half the distance from the CEJ to the incisal edge. It may blend with the palatal surface or stand away from the rest of the crown.

Trace talon

Enlarged or prominent cingula in any of its variants (i.e. conical, bifid or tubercle-like) originating from the cervical third of the root

Extra Cusp/ Accessory Cusp

They are the common variations of tooth morphology that are occasionally seen clinically [14]. The most commonly reported variations of accessory cusps are of 3 types: the Carrabelli cusps of the molars, Talon cusps of the incisors and Leong's tubercle of the premolar [15].

Presence of these additional extensions of tooth structure may pose various dental problems to clinicians such as caries in the pits or deep developmental grooves between the accessory cusp and the tooth [16] sensitivity or devitalisation of tooth due to fracture or attrition of the protruded portion of the cusp that has pulpal extension [17,18]. In the present study, accessory cusps are more commonly seen in maxillary teeth than the mandibular teeth.

Transposition

A dental transposition (or transmigration) occurs when teeth emerge in the wrong sequences in the dental arch, and the most common is when maxillary canine emerges distal to the first premolar [19]. Such teeth have been confused with supernumerary teeth but in reality, patients exhibit an increase prevalence hypodontia, not hyperdontia [10].

The etiology of canine ectopia and canine-premolar transposition is not known, but is assumed to be associated with multifactorial disorders involving genetic factors [20,21]. In the present study, transposition is also seen between canine premolar and found to be seen maximum in maxillary teeth than mandibular teeth i.e. out of 7 cases transposition, 6 cases were seen in maxillary dentition.

Fusion

Fusion may be partial or complete and may present with two independent root canals or less often, a single root and one or two pulp chambers [22]. In the present study, fusion accounted 14.6% of all of the dental anomalies and out of 19 cases of fusion, marked 13 cases were seen in mandibular teeth. Fusion was observed to occur unilaterally in accordance with other studies.²³Mandibular teeth were affected more than maxillary. Fusion can be suspected when the number of teeth in the arch is found to be reduced and/or two roots are seen radiographically [10].

Macrodonia

In present study only 3.8% of macrodonia were seen. Macrodonia, megalodontia, megadontia or gigantism occurs when a tooth, or teeth are larger than those considered to be within normal range; that is, they are outside the usual limits of variation. Macrodonia can be classified as true generalized, relative generalized and localized macrodonia in a manner similar to microdonia [24].

True generalized macrodonia, the condition in which all or at least the majority of the teeth are larger than normal. Relative generalized macrodonia, which is slightly more common, is the result of the presence of normal or slightly larger than normal teeth in relatively small jaws. Localized macrodonia is when a single tooth exhibits normal crown, root and pulp morphology except for the size [2].

Supernumerary teeth

Extra, or supernumerary, teeth in the dentition most probably result from continued proliferation of the permanent or primary dental lamina to form a third tooth germ. Supernumerary teeth are found more often in the permanent dentition than in the primary dentition and are much more commonly seen in the maxilla than in the mandible (10 to 1) [25].

Supernumerary teeth closely resemble the teeth of the group to which it belongs, i.e. molars, premolars or anterior teeth. Prevalence of supernumerary teeth was reported to be 0.8 % in primary dentition and 2.1% in permanent dentitions. Multiple supernumerary teeth are rare in individuals with no other associated disease or syndrome [24].

In our study only 2.3% cases are reported in present study and no supernumerary teeth were seen in permanent mandibular teeth.

CONCLUSION

The present study attempts to evaluate the frequency of occurrence of various developmental dental anomalies in a non-syndromic adult Indian population. It was duly recorded and noted that anomalies were more frequent in male patients than in females. Hyperdontia, fusion, peg shaped laterals (microdontia), and hypodontia were more frequent compared to other anomalies of size and shape. Developmental anomalies of teeth are clinically evident abnormalities. They may lead to various dental deformities. Careful observation and appropriate investigations are required to diagnose the condition and institute appropriate treatment. Early diagnosis can lead to early interception and thus treatment.

REFERENCES

1. Kruthika S Guttala ,Venkatesh G Naikmasurb Puneet Bhargavac ,Renuka J Bathid. Frequency of Developmental Dental Anomalies in the Indian Population. *European J Dent.* 2009;5:325-335.
2. Nigel M. King, S. Tongkoom, H.M. Wong. Morphological and Numerical Characteristics of the Southern Chinese Dentitions. Part III: Anomalies in the Primary Dentition. *The Open Anthropol J.* 2010;3(25-36):1874-9127.
3. Proffit WR. The development of orthodontic problems. In: *Contemporary orthodontics*, 2nd ed, Proffit WR ed, Mosby, St Louis, 1997; 110-112.
4. Shah RM, Boyd MA, Vakil TF. Studies of permanent tooth anomalies in 7886 Canadian individuals. I: impacted teeth. *Dent J.* 1978; 44: 262-264.
5. Al-Emran S. Prevalence of hypodontia and developmental malformation of permanent teeth in Saudi Arabian schoolchildren. *Br J Orthod.* 1990;17: 115-118.
6. Ooshima T, Ishida R, Mishima K, Sobue S. The prevalence of developmental anomalies of teeth and their association with tooth size in the primary and permanent dentitions of 1650 Japanese children. *Int J Paediatr Dent.* 1996; 6: 87-94.
7. Thongudomporn U, Freer TJ. Prevalence of dental anomalies in orthodontic patients. *Aust Dent J.* 1998; 43: 395-398
8. Hajrija Konjhodžić-Raščić, Amra Vuković, Selma Zukić, Anita Bajsmann, Alma Prcić. Dental Anomalies among Students of Faculty of Dentistry, University of Sarajevo. *Acta Medica Academica.* 2006;35:23-29.
9. Moorrees CFA. The dentition of the growing child. A longitudinal study of dental development between 3 and 18 years of age. *Vambridge, MA: Harvard University Press* 1959;115-119.
10. Neville DW, Damm DD, Allen CM, Bouquot JE. Abnormalities of teeth. In: *Oral and Maxillofacial Pathology*. 2nd ed. Philadelphia, PA: Elsevier; 2005:49-89
11. Mitchell WH. Case report. *Dent Cosmos.* 1892; 34: 1036.
12. Dash JK, Sahoo PK, Das SN. Talon cusp associated with other dental anomalies: a case report. *Int J Paediatr Dent.* 2004;14:295-300
13. Juan JS, Jiménez-Rubio A. Talon cusp affecting permanent maxillary lateral incisors in 2 family members. *Oral Surg Oral Med Oral Pathol Oral Radiol Endod.* 1999;88:90-92.
14. S. Nagarajan M.P. Sockalingam, Alida Mahyuddin. Bilateral accessory central cusp of 2nd deciduous molar: an unusual occurrence. *Arch Orofacial Sci.* 2009; 4(1): 22-24
15. Ooshima T, Ishida R, Mishima K and Sobue S. The prevalence of developmental anomalies of teeth and their association with tooth size in the primary and permanent dentitions of 1650 Japanese children. *Int J Paediatr Dent.* 1996; 6(2): 87-94
16. Rusmah M. Talon cusps in Malaysia. *Aust Dent J.* 1991; 36(1):11-14

17. GÜNGÖR HC, ALTAY N and KAYMAZ FF. Pulpal tissue in bilateral talon cusps of primary central incisors: report of a case. *Oral Surg Oral Med Oral Pathol Oral Radiol Endod.* 2000; 89(2): 231-235
18. STECKER S and DIANGELIS AJ. Dens evaginatus: a diagnosis and treatment challenge. *J Am Dent Assoc.* 2002; 133(2): 190-193.
19. Louise Miltenburg Caspersen, Ib Jarle Christensen, and Inger Kjær. Maxillary Canine Ectopia and Maxillary Canine-Premolar Transposition are Associated with Deviations in the Maxilla. *Dental Anthropol.* 2010; 23 (2): 37-41.
20. Feichtinger C, Rossiwall B, Wunderer H. Canine transposition as autosomal recessive trait in an inbred kindred. *J Dent Res.* 1977; 56:1449-1452.
21. Peck S, Peck L, Kataja M. The palatally displaced canine as a dental anomaly of genetic origin. *Angle Orthod.* 1994; 64:249-256.
22. Oliván-rosas G, López-jiménez J, Giménez-prats MJ, Piqueras-Hernández M. Considerations and differences in the treatment of a fused tooth. *Med Oral.* 2004;9:224-228
23. Hernández-Guisado JM, Torres-Lagares D, Infante-Cossío P, Gutiérrez-Pérez JL. Dental gemination: report of case. *Med Oral.* 2002;7:231-236
24. Shafer WG, Hine MK, Levy BM. *A textbook of oral pathology.* 5th ed. Philadelphia: WB Saunders Co 1983;53-65
25. JA Regezi, JJ Sciubba, RCK Jordan. *Oral pathology: clinical pathologic correlation.* Elsevier publication, Sauder. 1998; 3:371-375.